



UNIVERSITÀ  
DEGLI STUDI DI BARI  
ALDO MORO

MYCOLOGY

SHORT MASTER



# TASSONOMIA ED IDENTIFICAZIONE DEGLI ZIGOMICETI

*Claudia Cafarchia, Dipartimento di Medicina  
Veterinaria, Università degli Studi di Bari Aldo  
Moro.*

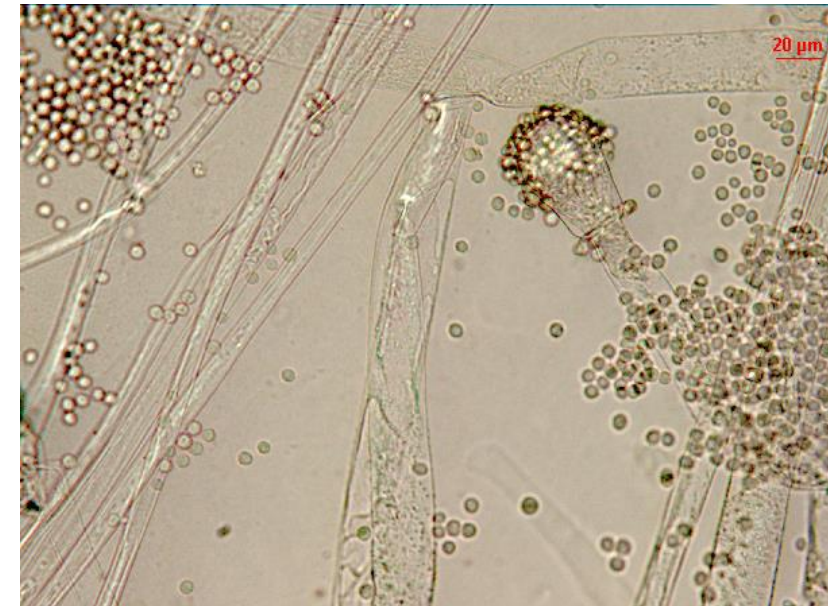
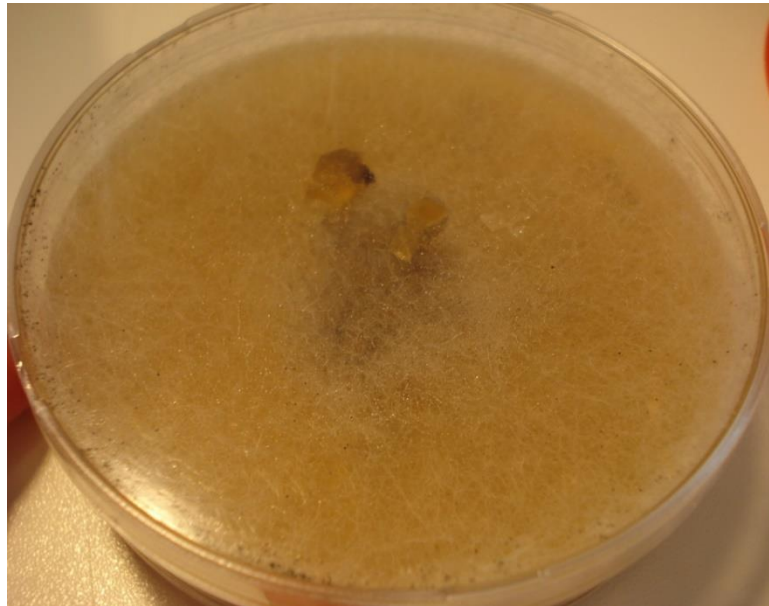DIPARTIMENTO  
MEDICINA  
VETERINARIA



# ZIGOMICETI

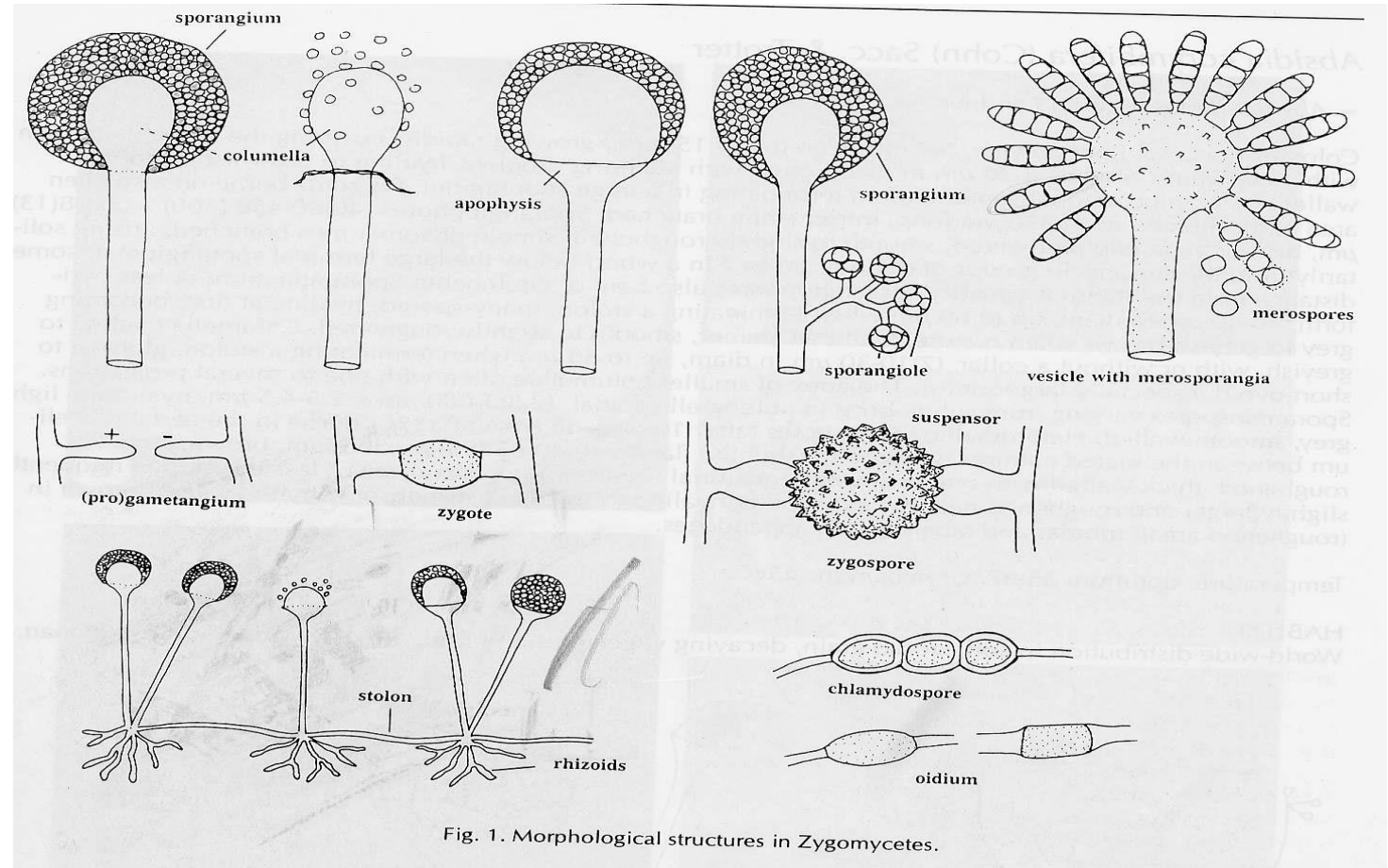
---

- Micelio cenocitico
- Zigospora
- Conidi prodotti in organi



# ZIGOMICETI

- Micelio cenocitico
- Zigospora
- Conidi prodotti in organi



# ZIGOMICETI

**ENTOMOPHTHORALES:** spora scaricata con la forza

**MUCORALES:** spore che origina dalla scissione del plasma dello sporangio

**MORTIERELLARES:** spore che origina dalla scissione del plasma dello sporangio

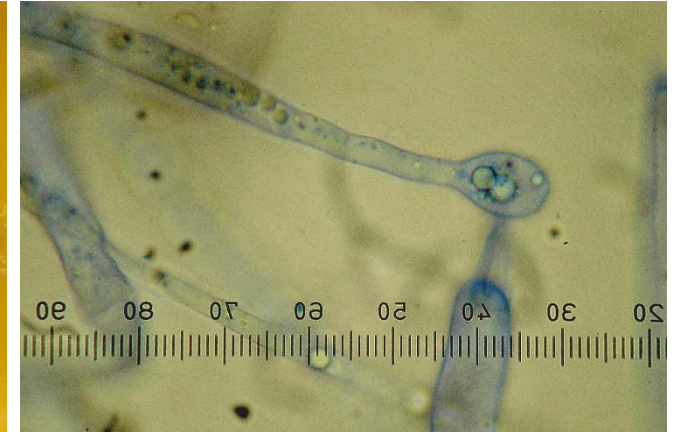Key to the medically relevant genera of Zygomycota:

1a.	Fungus forming cysts with endosporulation in the host; not growing on routine media → 2	
1b.	Fungus forming mycelium in the host; growth on most media rapid and abundant → 3	see <i>Rhinosporidium</i> (57)
2a.	Cysts prevailing in nasal mucosa	see <i>Pneumocystis</i> (131)
2b.	Cysts exclusively in lungs	
3a.	Spores single, borne on tubular sporophores, forcibly discharged, each with large, inflated scar at the base → ( <i>Entomophthorales</i> ) 4	
3b.	Spores arising in sporangia which are mostly multi-spored, passively discharged, with insignificant scars → ( <i>Mucorales, Mortierellales</i> ) 5	
4a.	Thallus hyphal, often becoming septate; sporophores elongate; spores with rounded tips	<i>Conidiobolus</i> (118)
4b.	Thallus often yeast-like; sporophores short; spores often conical	<i>Basidiobolus</i> (116)
5a.	Sporangia 1-spored or few-spored on small denticles on swollen cells → 6	
5b.	Sporangia multi-spored → 8	
6a.	Sporangia cylindrical, with spores in rows (merosporangia)	<i>Syncephalastrum</i> (113)
6b.	Sporangia with 1 or few spores (sporangiola) → 7	
7a.	Sporangiola on recurved stalks	<i>Cokeromyces</i> (72)
7b.	Sporangiola borne on the surface of large swellings	<i>Cunninghamella</i> (74)
8a.	Sporangia flask-shaped	<i>Saksenaea</i> (112)
8b.	Sporangia spherical or pyriform → 9	
9a.	Sporangia usually pyriform due to large apophyses of at least one fourth of the sporangium → 10	
9b.	Sporangia spherical; apophyses, when present, less than one fifth of the sporangium → 12	
10a.	Dark, septate chlamydospores formed in aerial mycelium	<i>Chlamydoabsidia</i> (70)
10b.	Dark, septate chlamydospores absent → 11	
11a.	Apophyses funnel-shaped	<i>Absidia</i> (62)
11b.	Apophyses vase-shaped	<i>Apophysomyces</i> (68)
12a.	Sporangia without columellae	<i>Mortierella</i> (76)
12b.	Sporangia with columellae → 13	
13a.	Sporangia with apophyses; sporangiophores in groups, unbranched	<i>Rhizopus</i> (101)
13b.	Above characteristics not combined → 14	
14a.	Rhizoids present	<i>Rhizomucor</i> (94)
14b.	Rhizoids absent	<i>Mucor</i> (81)

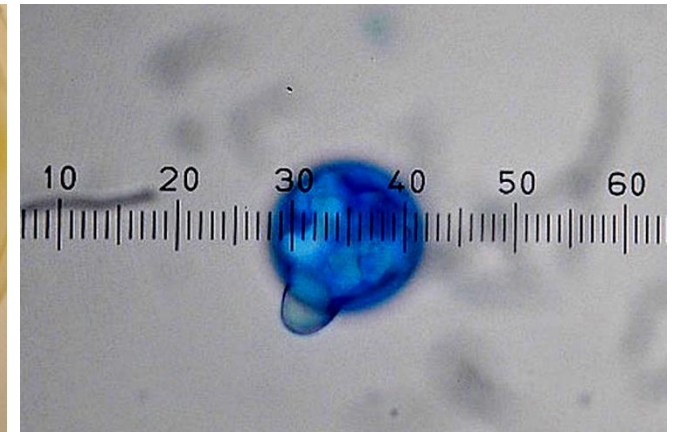
# ENTOMOPHTHORALES

---

**Basidiobolus:** tallo yeast like  
sporofori corti, spore coniche



**Conidiobolus:** sporofori allungati e  
spore con una apice arrotondato



# MUCORALES

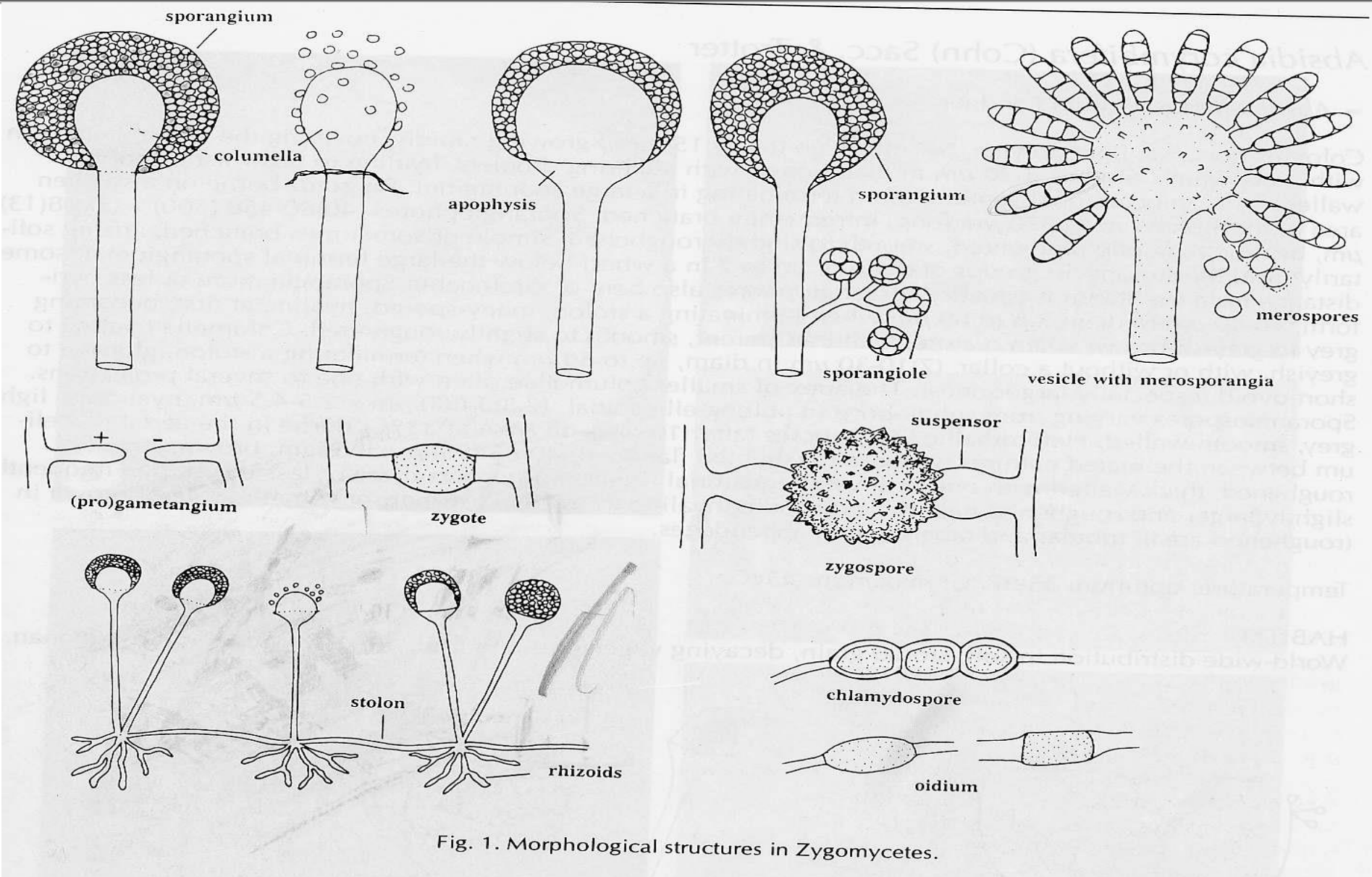


Fig. 1. Morphological structures in Zygomycetes.

# MUCORALES

---

***Mucor***: columelle sferiche con colletto senza rizoidi

***Absidia***: columella piriforme e apofisi

***Rhizopus***: columella a cappello di fungo, sporangi scuri con apofisi, presenza di rizoidi

***Thamnidium***: piccoli sporangioli

***Syncephalastrum***: merosporangi



Fig. 8 *Mucor*: columella e sporangio

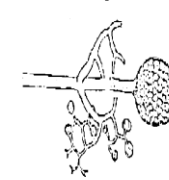


Fig. 9 *Thamnidium*: sporangio

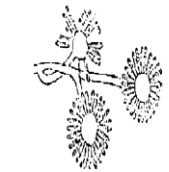
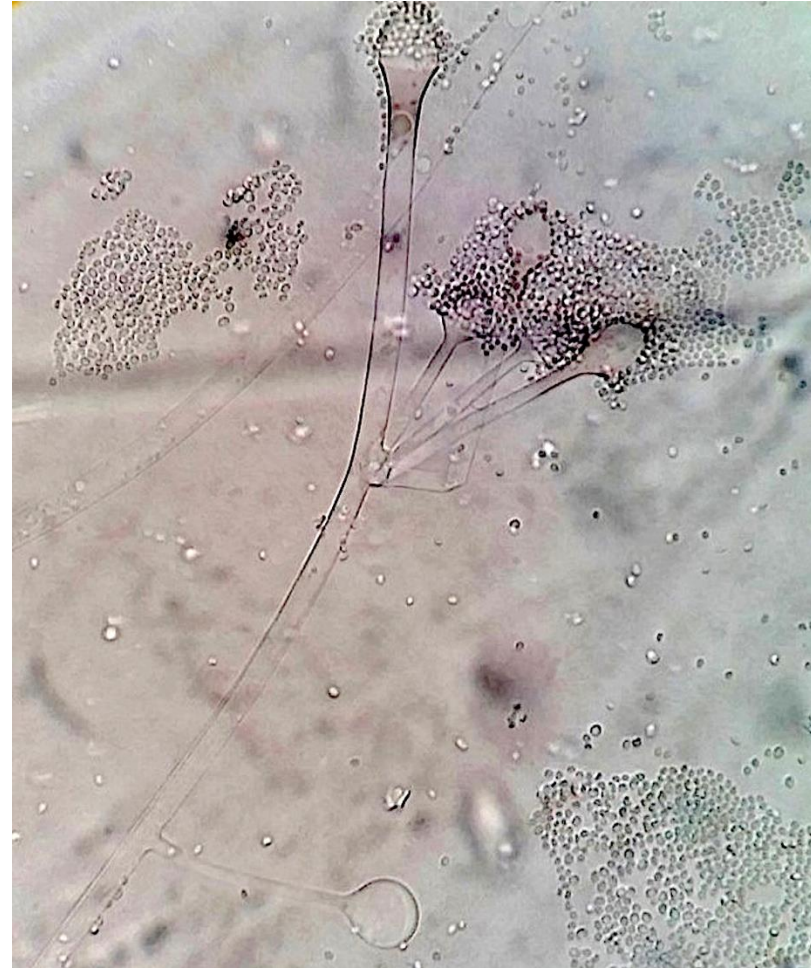
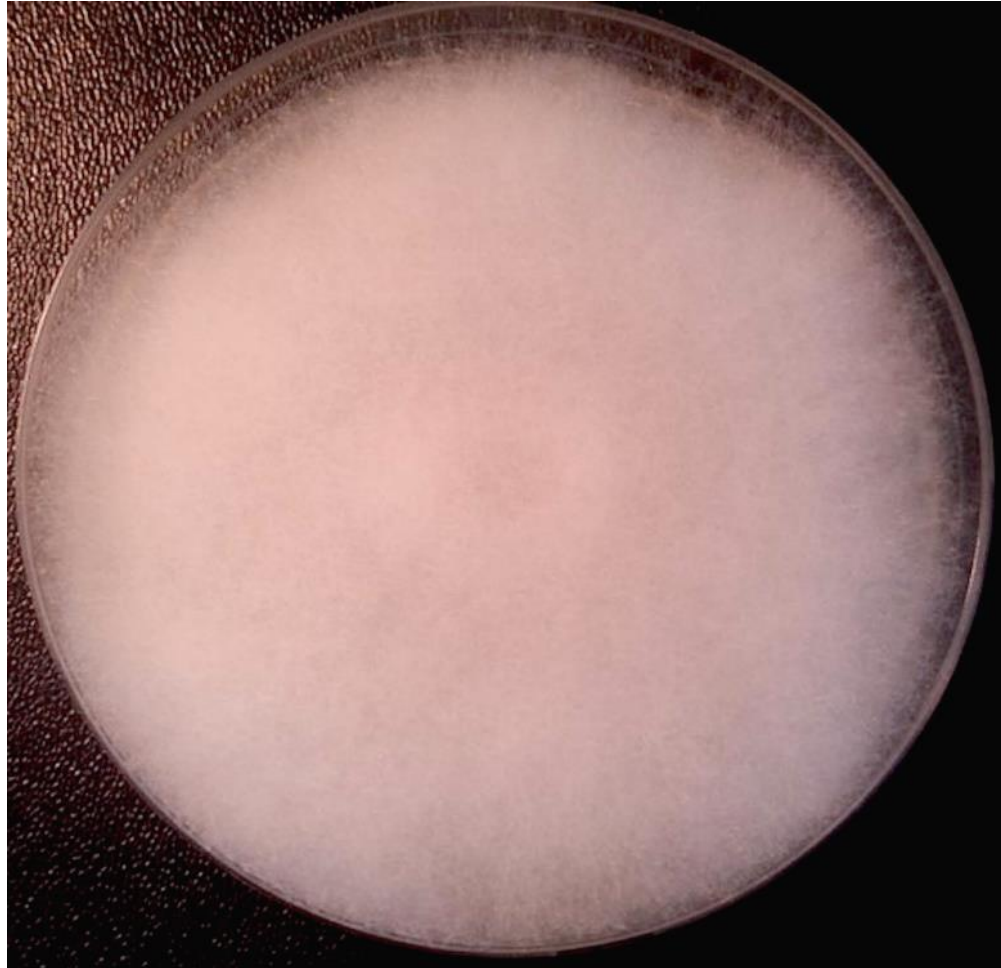
Fig. 10 *Syncephalastrum*: sporangio

# MUCORALES

---





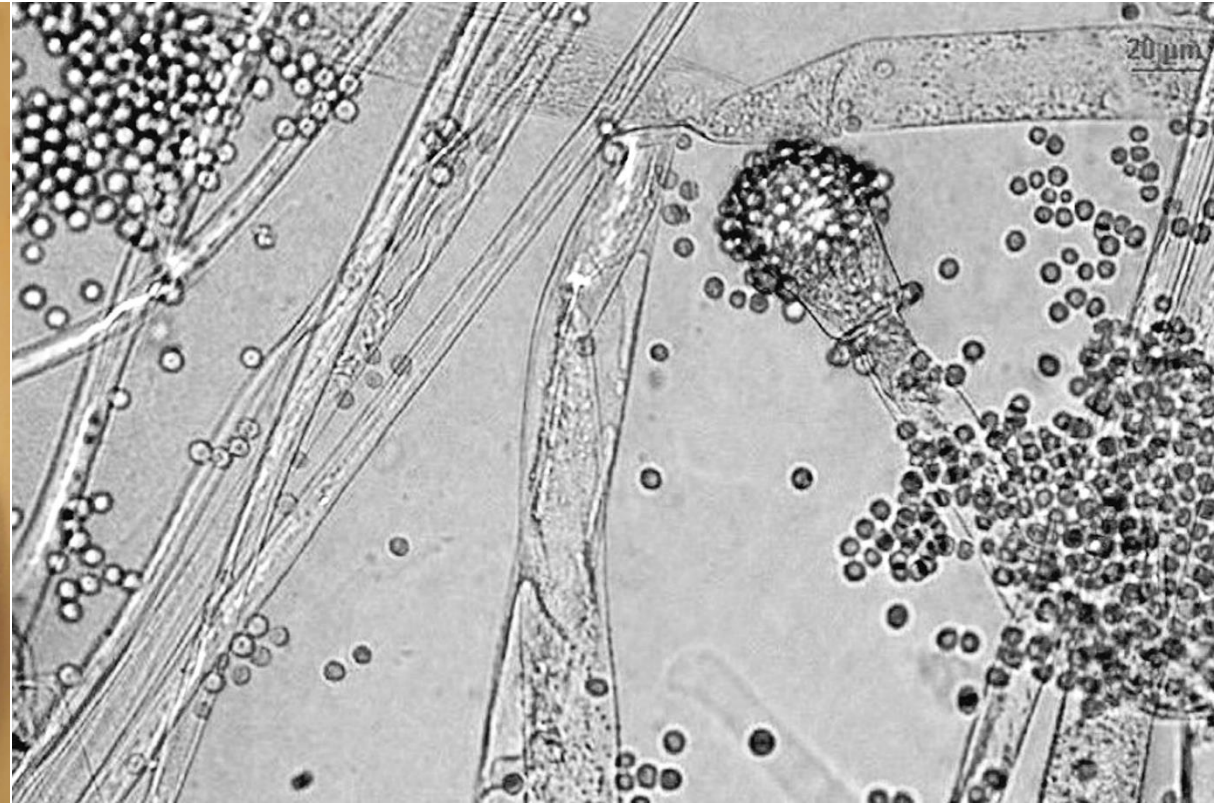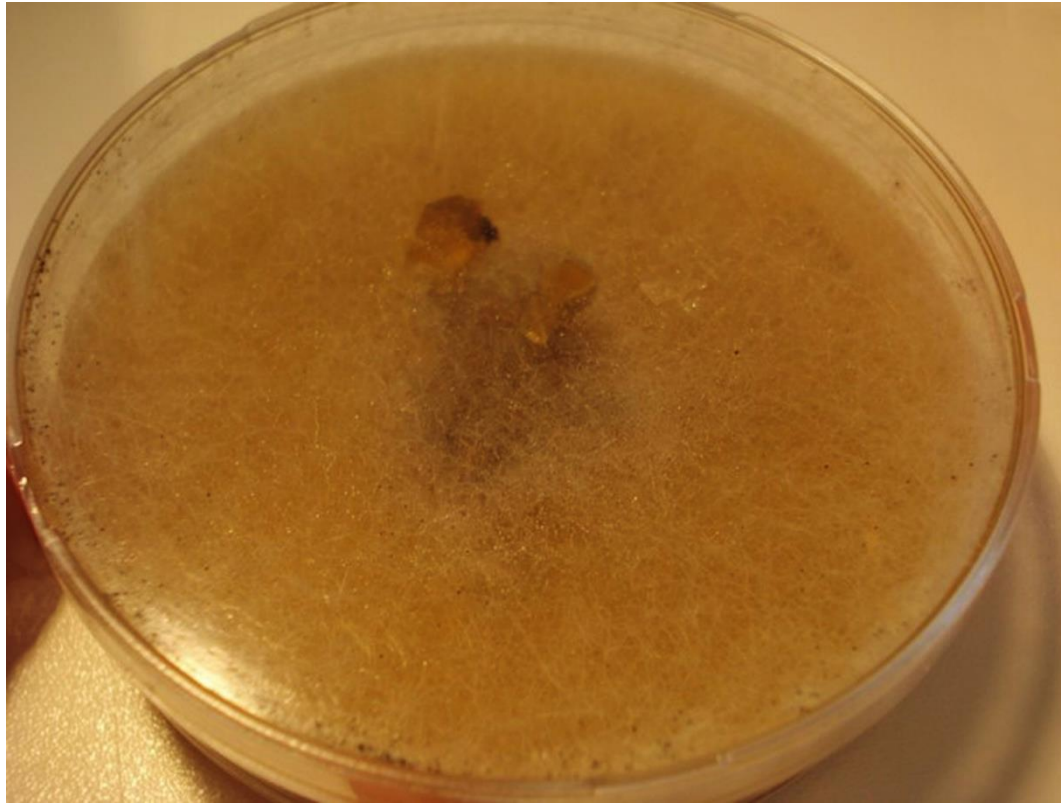
# MUCORALES

---



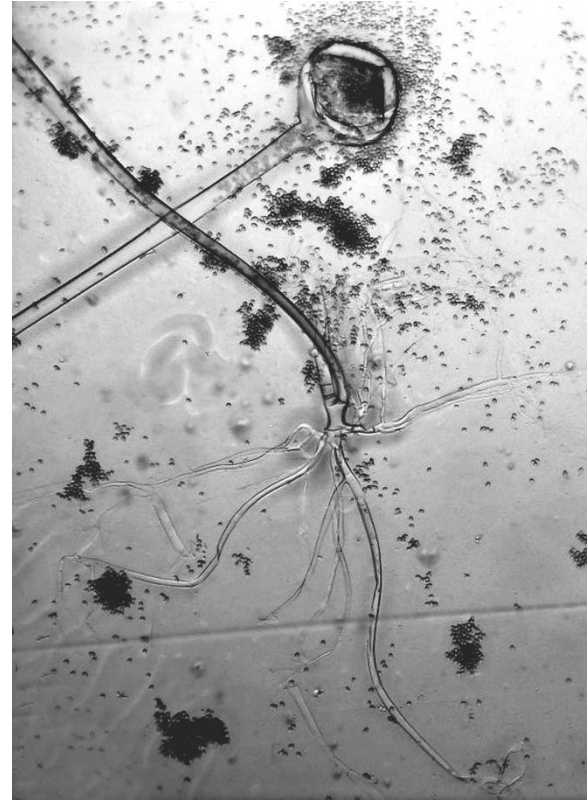# MUCORALES

---



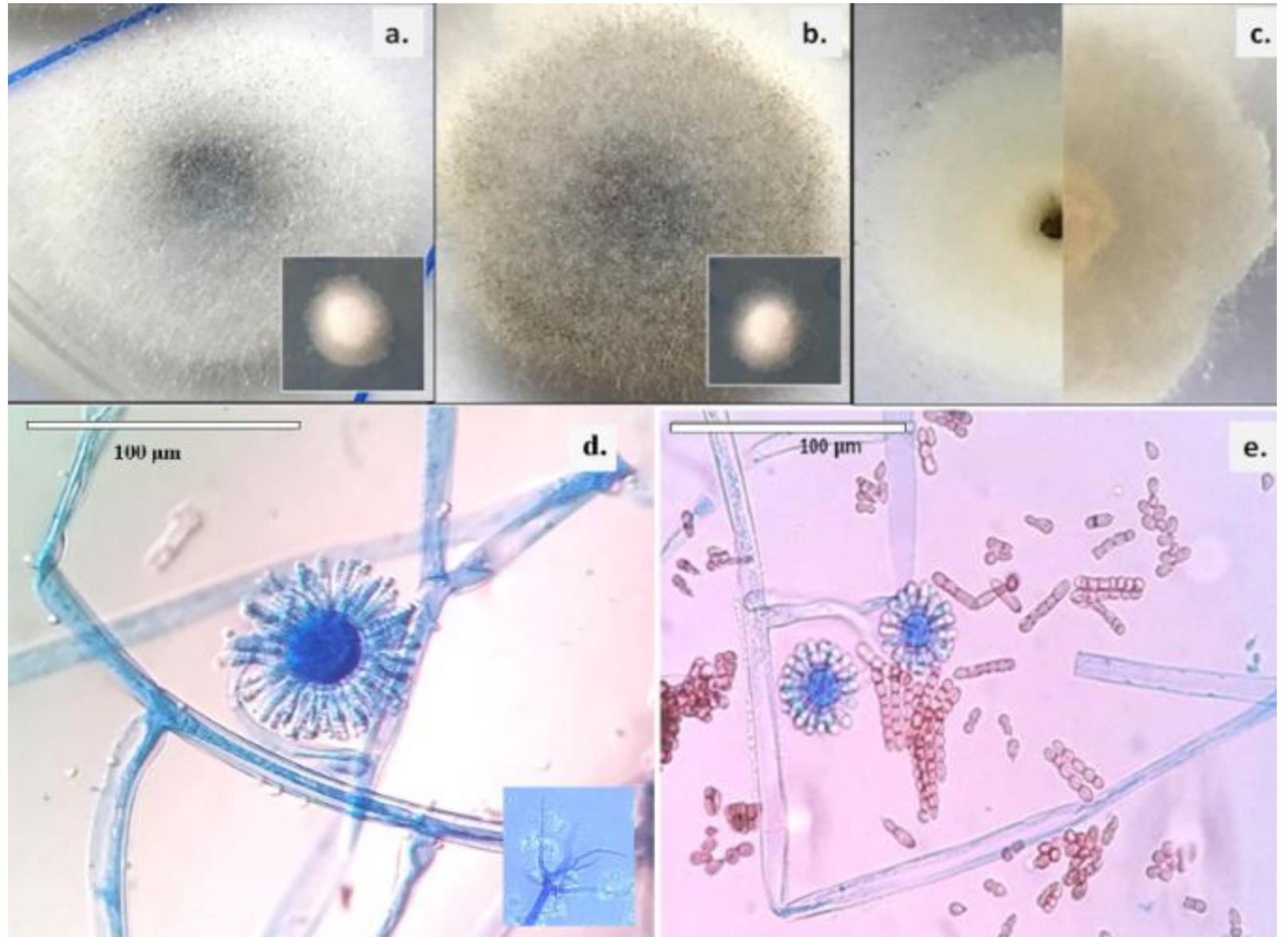
# MUCORALES

---



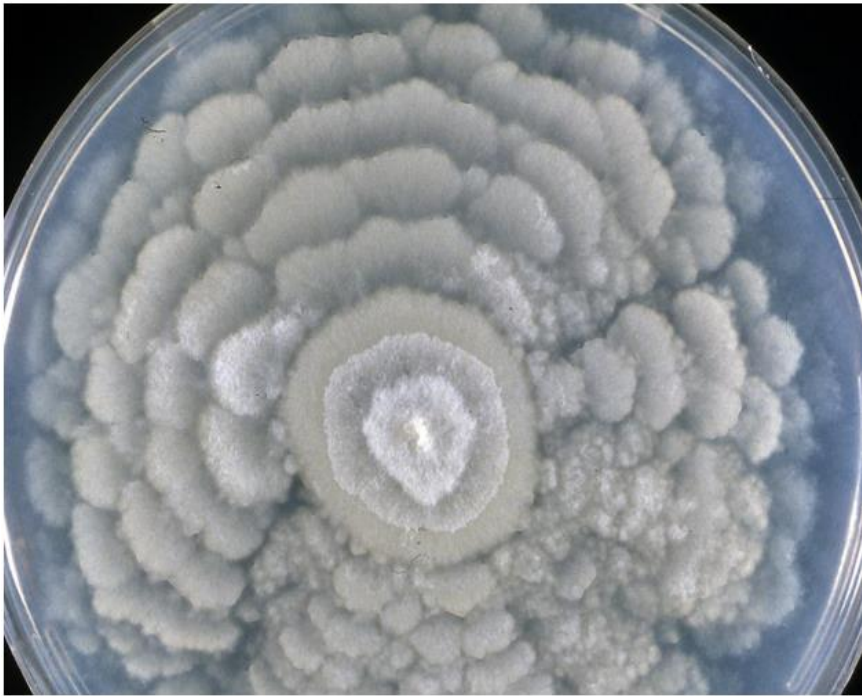# MUCORALES

---

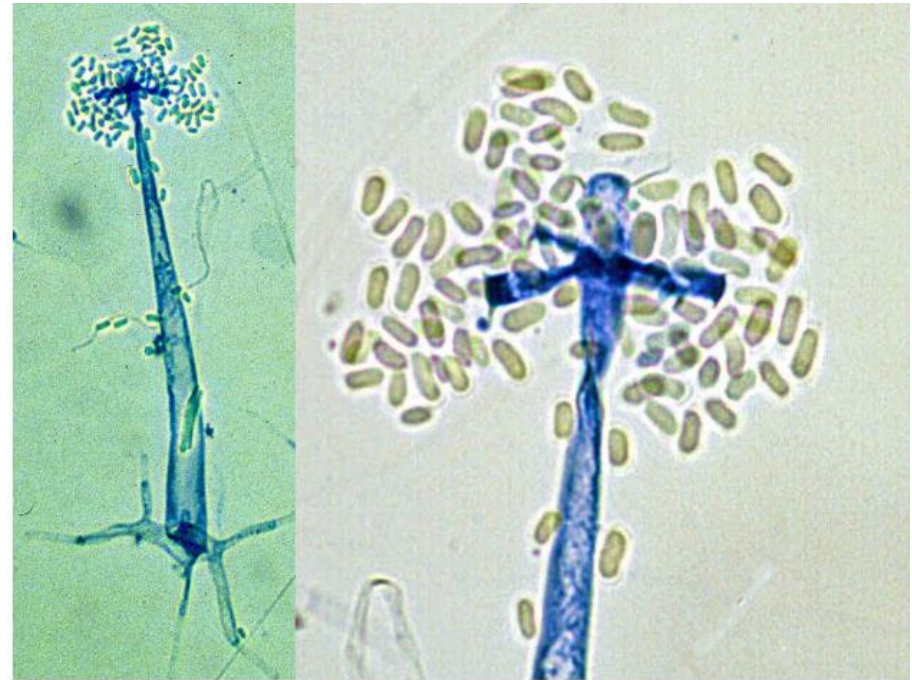


# Mortierellales

---



Culture of *Mortierella wolfii*.

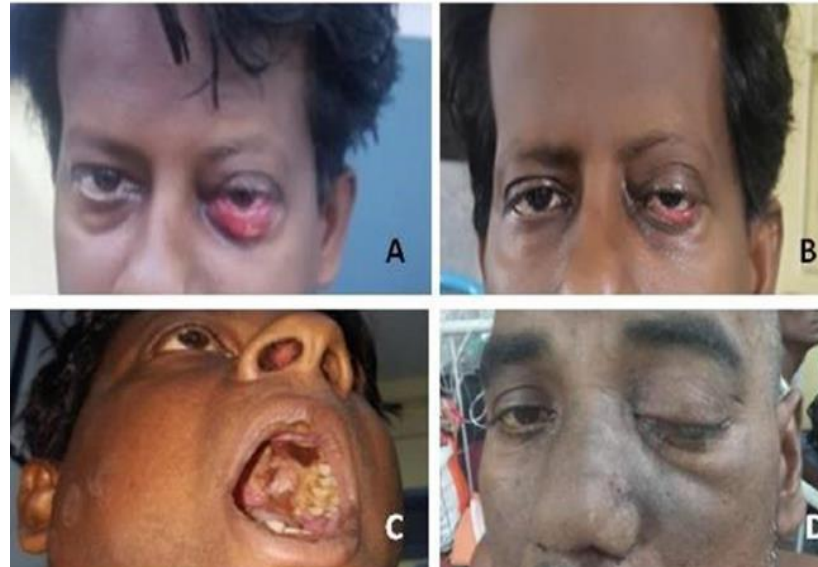
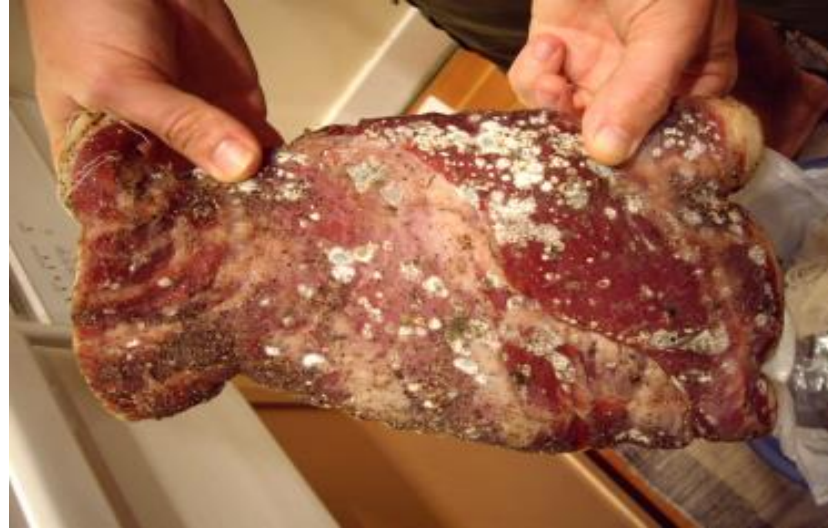
Sporangium with acrotonous (terminal) branches and rhizoids of *Mortierella wolfii*.

<https://www.adelaide.edu.au/mycology/fungal-descriptions-and-antifungal-susceptibility/zygomycota-pin-moulds/mortierella-wolfii>

# Caratteristiche

- Muffe gliofile e/o lipofile: no cellulosa
- Necessitano di vitamine
- Parzialmente anaerobe
- Esigenti in umidità



# PATOGENICITA'

SPECIE ANIMALE	SPECIE FUNGINA	SEGNO CLINICO	LESIONE A.P.*	Diagnosi	AUTORE
Ornitorinco	<i>Mucor amphibiorum</i>	Piogranulomi cutanei. cute ulcerata: collo testa coda	Numerosi granulomi polmonari $\leq$ 1mm	Coltura e microscopico	Obendorf et al., 1993
Bovino	<i>Absidia corymbifera</i>	Abbattimento, anoressia, diarrea	Ulcere nell'app. gastroenterico. Ascessi in abomaso	Coltura	Jensen et al., 2004
Vitelli (3gg di età)	<i>Rhizomucor spp.</i>	Abbattimento, sclere iperemiche, endoftalmite	Granulomi di piccole dimensioni: miocardio, fegato, reni, milza ed encefalo. Necrosi e trombosi dei vasi cerebrali	Coltura	Vasconcelos et al., 1995
Vacca	<i>Mortierella wolfii</i>	Letargia, atassia, cecità, aborto	Assottigliamento e opacità delle meningi, petecchie . Emorragia polmonare	PCR da tessuto cerebrale	Munday et al., 2006
Vacca	<i>Lichtemia corymbifera</i>	Aborto	Necrosi cotiledonare, placentite con essudato, vasculite.	PCR	Piancastelli et al., 2009
Equino	<i>Rhizopus stolonifer</i> <i>Aspergillus niger</i>	Apatia, febbre, dispnea, lacrimazione	Essudato schiumoso dalle narici Polmoni aumentati di volume, congesti, presenza di noduli nel parenchima	Coltura di polmoni, fegato e milza	Carrasco et al., 1997
Cane (Dobermann, 4 anni femmina, sterilizzata)	<i>Absidia corymbifera</i>	Incontinenza urinaria, masse addominali, al polo craniale rene destro , e cranialmente al pube. Eseguita eutanasia	Tessuto granulomatoso in addome; idronefrosi rene destro; vescica invasa da tessuto granulomatoso	Coltura Tessuto granulomatoso	Vulcano et al., 2005
Cervo	<i>Mucorales spp. et Cl. perfringens</i>	Morte improvvisa	Prestomaco disteso, ecchimosi della sierosa. Linfonodi intestinali aumentati di volume	Coltura e microscopico	Sato _Matsuura, 1998
Phocoena phocoena (cetaceo)	<i>Rhizopus spp</i>	Rinvenuto già morto	Emaciazione, e noduli su e reni. Linfonodi polmonari aumentati di volume.	Coltura e microscopico	Wünschmann et al., 1999
Gatto	<i>Rhizomucor spp.</i>	Inappetenza, febbre, perdita di peso. Perforazione duodenale e distensione addominale, per raccolta di fluido	Duodeno con infiltrato infiammatorio	Coltura e microscopico	Cunha et al., 2011

# PATOGENICITA'

**Table 1**  
Clinical description of the 7 cases of *Syncephalastrum* infections.

Case no.	NCCPF ID	Age/Gender	Site of infection	Clinical presentation	Duration of illness	Risk factors	Mycological Investigations	Radiology	Identification	AFST (MIC - µg/ml) Amb Itr Pos Ter	NCBI Accession no.	Treatment	Outcome
1	610,006	40/M Chandigarh	Subcutaneous	Nodule on hand	1 month	Agricultural worker (possible trauma)	KOH+, Culture+	NA	<i>S. racemosum</i>	0.25 0.5 0.25 0.06	MN192182	ITR	Recovered
2	610,007	38/F Jammu	Superficial	Deformed nails of bilateral big toe with hypertrophy and discoloration suggestive of onychomycosis	1 year	None	KOH+, Culture+	NA	<i>S. monasporum</i>	0.25 2 1 0.12	MN192176	TBF	LFU
3	610,009	44/M (Pondicherry)	Subcutaneous	Diffuse swelling in lateral aspect of right thigh progressing to focal cutaneous necrosis with multiple discharging sinuses	4 months	History of incision and drainage of suspected abscess in the same region 2 months ago	Locally debrided tissue was KOH+, Culture+, HP+ (PAS stain)	NA	<i>S. monasporum</i>	0.12 1 0.5 0.06	MN192177	ITR 200 mg BD for 4 weeks	Recovered
4	610,010	59/M (New Delhi)	Subcutaneous	Nasal obstruction, mouth breathing and snoring	2 months	History of surgery for ureteric calculi 1 year ago	Debris from right sinus exploration KOH+, Culture+	CT scan PNS: Mucosal thickening in sphenoid sinus suggestive of chronic sinusitis. Subtle mucosal thickening at the floor of right maxillary sinus. Left deviation of nasal septum with septal spur.	<i>S. monasporum</i>	0.12 1 1 0.06	MN192179	Septoplasty with coablation assisted turbinate reduction ITR 100 mg BD for 15 days	Recovered
5	610,011	24/M (Chandigarh)	Invasive	Fever, shortness of breath, cough with expectoration and bleeding from tracheostomy tube	4 days	History of road traffic accident with polytrauma and multiple fractures. Patient was under intensive care for 2 weeks.	Tracheal secretions were culture positive	chest x-ray bilateral chest infiltrates	<i>S. racemosum</i>	0.5 1 0.5 0.06	MN192178	No antifungal initiated	death



# PATOGENICITA'

Table 1 (continued)

Case no.	NCCPF ID	Age/Gender (Kolkatta)	Site of infection	Clinical presentation	Duration of illness	Risk factors	Mycological Investigations	Radiology	Identification	AFST (MIC - µg/ml) Amb Itr Pos Ter				NCBI Accession no.	Treatment	Outcome
6	610,012	40/M (Kolkatta)	Invasive	Necrotic oral ulcer over the hard palate with nasal obstruction progressing to orbital involvement and visual impairment on the left eye associated with severe pain	1.5 months	Diabetes (Type II) with ketoacidosis, chronic kidney disease (stage 4) due to IgA nephropathy on long term steroids and hemodialysis	Scraping from hard palate KOH+, Culture+	CT PNS: Left sided maxillary antrum opacity suggestive of pansinusitis Repeat CT: Progressing sinusoidal opacity toward the retro orbital space and a bulky oedematous left inferior rectus	<i>S. racemosum</i>	0.5	0.5	0.5	0.06	MN192180	Endoscopic sinus debridement with topical LAmb. Intravenous LAmb 300 mg daily OD for 3 weeks and later shifted to voriconazole 200 BD	Recovered
7	610,013	52/M (Kolkatta)	Invasive	Left sided hemicranial headache, disoriented with neck rigidity along with 2nd, 3rd, 4th, 6th and 7th cranial nerve palsy left sided facial weakness and ophthalmoplegia, nasal mass	1 month	Uncontrolled Diabetic (Type II)	Endoscopy debrided sinus material KOH +, Culture+	MRI brain: Multiple small infarcts in left fronto-parital subcortical white matter. CT PNS: Sinusitis with thickening oedematous extraocular muscles of left orbit.	<i>S. racemosum</i>	0.5	1	1	0.12	MN192181	Lamb for 3 weeks	Improvement but persistence of neurological deficit.
8	610,014	39/M (Chandigarh)	Invasive	Left sided headache with ptosis and loss of vision in left eye. Frozen left eye on examination	20 days	Uncontrolled Diabetic (Type II)	Endoscopy debrided sinus material KOH +, Culture+	MRI brain and orbit: Orbital cellulitis and secondary ethmoidal cell involvement. CT PNS: paranasal sinusitis with mucosal thickening	<i>S. monasporum</i>	0.12	1	0.5	0.06	submitted	Anterior And posterior ethmoidectomy with orbital exenteration and Lamb for 3 weeks	Improvement

KOH potassium hydroxide mount (+indicates the presence of aseptate hyphae on direct microscopy), HP histopathology (+indicates the presence of aseptate hyphae with right angle branching on histopathological examination), ITR: itraconazole, TBF: terbinafine, Lamb: liposomal amphotericin B.